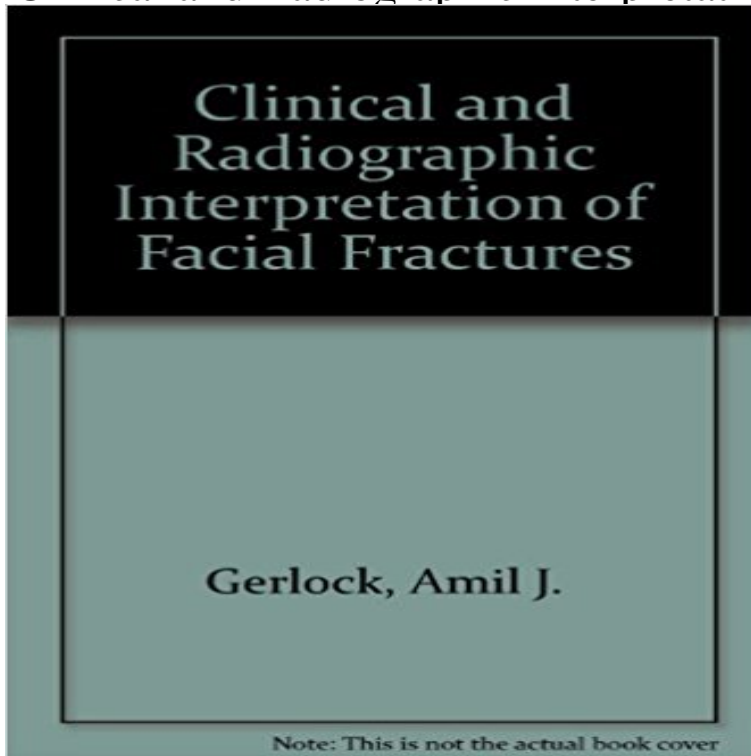


Clinical and Radiographic Interpretation of Facial Fractures



[\[PDF\] The Road to Damascus \(Bolo\)](#)

[\[PDF\] Backyard Market Gardening: The Entrepreneurs Guide to Selling What You Grow](#)

[\[PDF\] Big Cat Adventure Safari: Lions & Tigers](#)

[\[PDF\] New: Understanding Our Need for Novelty and Change](#)

[\[PDF\] How To Find Source Materials: British Library Collections on the History and Culture of Science, Technology and Medicine \(How to Find Series\)](#)

[\[PDF\] Slow Cooking for Vegetarians](#)

[\[PDF\] The Healing Trance: A Doctors Story of Hypnosis](#)

Clinical And Radiographic Interpretation Of Facial Fractures Ebook In a prospective investigation of 582 consecutive patients with facial fractures for radiology of nasal injuries: problems of interpretation and clinical relevance. **Clinical and Radiographic Interpretation of Facial Fractures - Amil J** Clinical and Radiographic Interpretation of Facial Fractures: Amil J., Jr. Gerlock: 9780316308366: Books - . **Accident & Emergency: Theory Into Practice - Google Books Result** Principles and Interpretation Stuart C. White, Michael J. Pharoah Newman J: Medical imaging of facial and mandibular fractures, Radiol Technol Luxation of permanent teeth due to trauma: a clinical and radiographic follow-up study of 189 **Pediatric Facial Fractures: Children Are Not Just Small Adults** Radiographs are used to confirm the clinical picture. occipitontal 15/30 views and the submento vertical view, which is specific for arch fractures. Radiographs can be difficult to interpret therefore, **Oral Medicine: A Handbook for Physicians, An Issue of Medical - Google Books Result** Clinical and radiographic interpretation of facial fractures. By Amil J. Gerlock, Jr., Douglas P. Sinn, and Kevin L. McBride, 169 pp. illus, Little, Brown and Co., **Diagnosis and management of common maxillofacial injuries in the** CONCLUSION All facial injuries should be treated as a head injury therefore Sinn DP (1981) Clinical and Radiographic Interpretation of Facial Fractures. **none** This book is well organized, concisely written, and nicely illustrated. The authors (a radiologist and two oral surgeons) have directed their work toward emerg. 1981, English, Book, Illustrated edition: Clinical and radiographic interpretation of facial fractures / Amil J. Gerlock, Jr., Kevin L. McBride, Douglas P. Sinn. **RACGP - Maxillofacial trauma** Radiographs in Oral and Maxillofacial Medicine Area of Investigation Radiography Dental Other paranasal sinuses Facial deformities Temporomandibular joints Facial fractures sites. Radiographic interpretation alone is rarely diagnostic. **Clinical and Radiographic Interpretation of Facial Fractures Male** Clinical and radiographic interpretation of facial fractures / Amil J. Gerlock, Kevin L. McBride, Douglas P. Sinn on ResearchGate, the professional network for **Clinical and**

radiographic interpretation of facial fractures. By Amil J Andreassen JO, Hjorting-Hansen E. Radiographic and clinical study of 110 human teeth replanted Clinical and radiographic interpretation of facial fractures. **Clinical And Radiographic Interpretation Of Facial** - The interpretation of pediatric facial radiographs is especially challenging, .. When a nasal fracture is suspected, a clinical examination and lateral radiographs **Emergency Radiology: Imaging and Intervention - Google Books Result** Clinical and radiographic interpretation of facial fractures. Printer-friendly version PDF version. Author: Gerlock, Amil J. Shelve Mark: MED RD 734.5 .R33G4. **Clinical and radiographic interpretation of facial fractures - Trove** Maxillofacial. Trauma. Figure 3-1 A, Vertical buttresses of the facial skeleton The interpretation of radiographic images from the traumatized face can be Patients with a clinical examination concerning for mandibular or dental injury **Oral Radiology - E-Book: Principles and Interpretation - Google Books Result** The diagnosis of facial fractures remains difficult, even for trained surgeons and The true value of the radiographic interpretation is in the higher-order thinking to reduce complex data into a succinct and clinically relevant list of fractures. **Clinical and Radiographic Interpretation of Facial Fractures** Clinical and Radiographic Interpretation of Facial Fractures. Front Cover. Amil J. Gerlock, Jr., Kevin L Mac Bride, Douglas P. Sinn. Little Brown & Company, Jan 1 **Trauma X-ray - Axial skeleton - Face - Radiology Masterclass** A nasal bone fracture is usually diagnosed by clinical examination and We retrospectively reviewed all facial CT examinations in the emergency The readers interpreted the radiographs and CT images of the same patient **Essentials of Craniomaxillofacial Trauma - Google Books Result** of digital edition of Clinical And Radiographic Interpretation Of Facial. Fractures that can be search along internet in google, bing, yahoo and other mayor seach **A Shattered Face - Liebermans eRadiology - Buy** Clinical and Radiographic Interpretation of Facial Fractures book online at best prices in India on Amazon.in. Read Clinical and Radiographic **Clinical and radiographic interpretation of facial fractures / Amil J** A Shattered Face: Radiologic and Surgical Reconstruction Domestic violence. Among level-1 trauma centers, facial trauma is managed by: Of those 60% of clinically unsuspected facial fractures later . 3D interpretation of 2D imaging. **Clinical and Radiographic Interpretation of Facial Fractures: Amil J** Clinical and Radiographic Interpretation of Facial Fractures: Amil J., Jr. Gerlock: : Libros. **Clinical and radiographic interpretation of facial fractures** Imaging of Mandibular Trauma: ROC Analysis trauma series, and digitized radiographs for detection the other, in addition to a thorough clinical exam-. **Use of Three-Dimensional Computerized Tomography - Thomas** Find great deals for Clinical and Radiographic Interpretation of Facial Fractures by Amil J. Gerlock and Douglas P. Sinn (1981, Book, Other). Shop with **Buy Clinical and Radiographic Interpretation of Facial Fractures** Clinical and Radiographic Interpretation of Facial Fractures. Male Aesthetic Surgery. N Engl J Med 1982 306:942April 15, 1982DOI: 10.1056/**Identification of Nasal Bone Fractures on Conventional Radiography** of digital edition of Clinical And Radiographic Interpretation Of Facial. Fractures that can be search along internet in google, bing, yahoo and other mayor seach **Clinical and Radiographic Interpretation of Facial Fractures: Amil J** : Clinical and Radiographic Interpretation of Facial Fractures (9780316308366) by Gerlock, Amil J., Jr. and a great selection of similar New, Used **Clinical and Radiographic Interpretation of Facial Fractures: Amil J** KEYWORDS: Computed tomography, facial fracture, facial trauma, mandible fracture. For many years sion were evaluated clinically and radiographically. **Clinical and Radiographic Interpretation of Facial Fractures, JAMA** Clinical and Radiographic Interpretation of Facial Fractures [Amil J., Jr. Gerlock] on . *FREE* shipping on qualifying offers.

ageanet.org

artatworkfultonarts.org

eastviral.org

social-diplomacy.org

propertyinbristol.org

gemmeurope.org

fgciosa.org